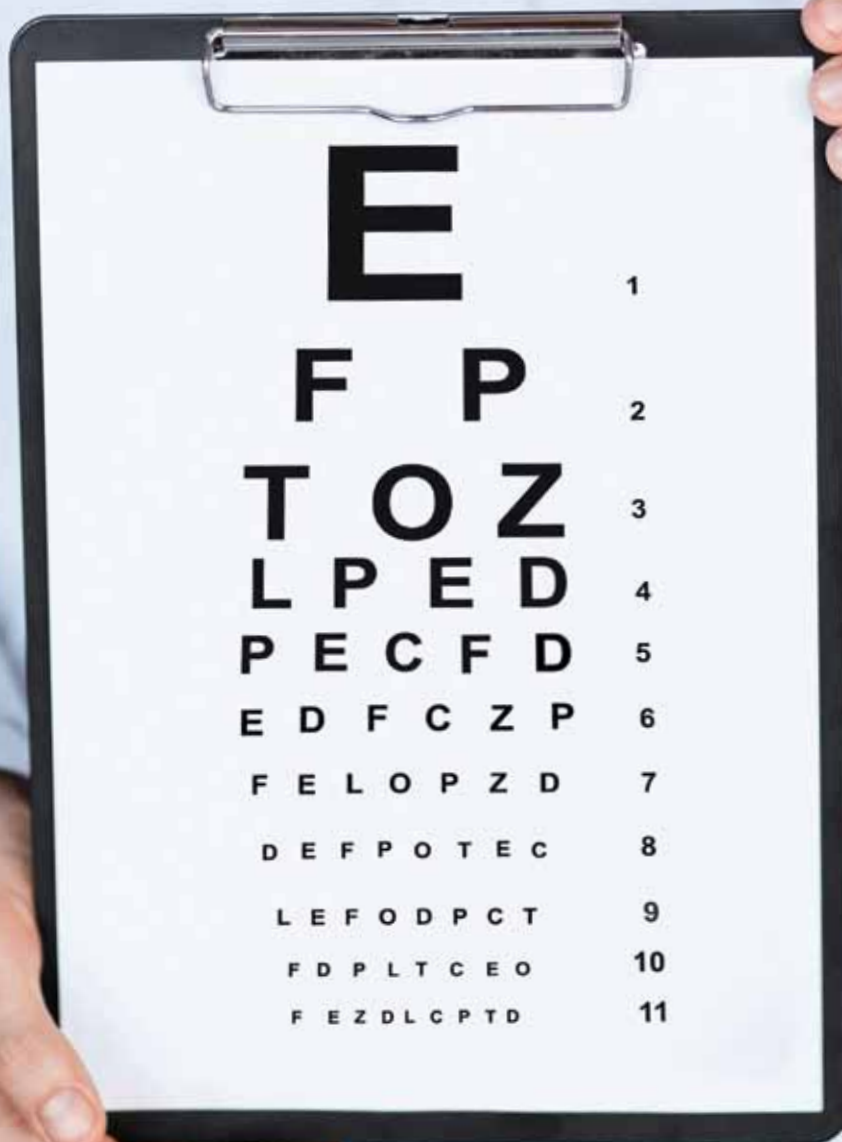

APR - JUN 2017

# médico

A QUARTERLY PUBLICATION OF **GP LIAISON CENTRE, NATIONAL UNIVERSITY HOSPITAL**

MCI (P) 123/03/2017



## OPHTHALMOLOGY

IN THIS  
ISSUE

- **AGE RELATED MACULAR DEGENERATION**
- **CATARACT TREATMENT & MANAGEMENT**

- **DIABETIC RETINOPATHY**
- **EYE REHABILITATION PROGRAMME**
- **STRABISMUS**

# WHAT'S INSIDE

APR - JUN 2017

## IN FOCUS

Eye Care @ NUH 03

## LANDSCAPE

**Diabetic Retinopathy -** 04  
Screening in the  
Community and Updates  
in Latest Management  
Guidelines

## INSIGHTS

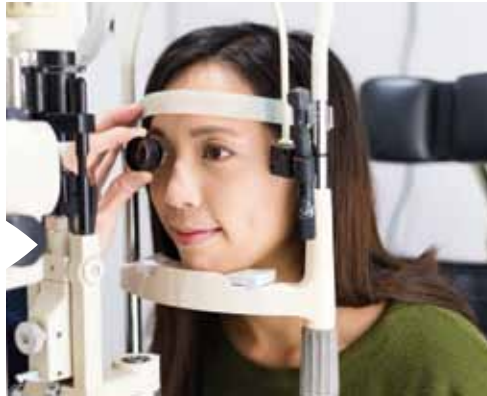Strabismus 07  
Age-Related Macular  
Degeneration 08

## TIPS

Floaters, Flashes, Posterior  
Vitreous Detachment and  
Retinal Detachment 10

## TREATMENT ROOM

**Seniors' Eye Rehabilitation** 12  
**Programme -**  
Helping Seniors with Low  
Vision Live Independently  
**Cataract Treatment** 16  
**and Management**



## IN ADDITION

18 **Extraordinary Service  
for an Ordinary Problem -**  
NUH Ophthalmology  
Cataract Suite

## SPECIALIST IN FOCUS

20 Dr Victor Koh

## HAPPENINGS @ NUH

24 **Post Event Highlights**  
27 **Upcoming Events**



We will love to hear your feedback on **médico**

Please direct all feedback to:

**The Editor, médico**

GP Liaison Centre, National University Hospital, 1E Kent Ridge Road,  
NUHS Tower Block, Level 6, Singapore 119228

Tel: 6772 5079

Email: [gp@nuhs.edu.sg](mailto:gp@nuhs.edu.sg)

Fax: 6777 8065

Website: [www.nuh.com.sg/nuh\\_gplc](http://www.nuh.com.sg/nuh_gplc)

Co. Reg. No. 198500843R

### The NUHS Group

National University Hospital  
National University Cancer Institute, Singapore  
National University Heart Centre, Singapore  
National University Centre for Oral Health, Singapore  
National University Polyclinics  
Ng Teng Fong General Hospital

Jurong Community Hospital  
Jurong Medical Centre  
NUS Yong Loo Lin School of Medicine  
NUS Alice Lee Centre for Nursing Studies  
NUS Faculty of Dentistry  
NUS Saw Swee Hock School of Public Health

### A Publication of NUH GP Liaison Centre (GPLC)

**Advisor**  
A/Prof Goh Lee Gan

**Editors**  
Stella Lee  
Karin Lim

**Editorial Member**  
Yvonne Lin

The information in this publication is meant purely for educational purposes and may not be used as a substitute for medical diagnosis or treatment. You should seek the advice of your doctor or a qualified healthcare provider before starting any treatment, or, if you have any questions related to your health, physical fitness or medical condition(s).

Copyright (2017). National University Hospital, Singapore

All rights reserved. No part of this publication may be reproduced without permission in writing from National University Hospital.

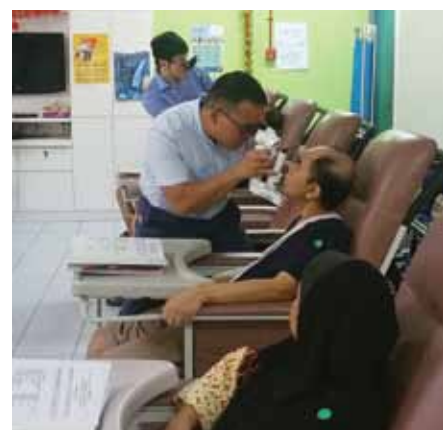

# EYE CARE @ NUH

The Department of Ophthalmology was started in 1986 by the late Prof Arthur Lim. Since then, it has grown to a full-service eye department, offering the full range of ophthalmic sub-specialties. Our specialists are

capable of managing the breadth of ophthalmic diseases, from common blinding eye diseases such as cataracts, glaucoma, diabetic retinopathy and age-related macula degeneration to rare conditions such as ocular inflammations and genetic diseases.

We believe in staying at the forefront of the scientific and technological advances in ophthalmology, and have invested in equipment and training to bring these to our patients. Some examples of these are femtosecond laser cataract surgery, minimally invasive glaucoma surgery, and micropulse diode laser for treatment of glaucoma (developed by Associate Professor Paul Chew). Beyond this, we have also invested in developing programmes to empower community healthcare providers to



perform eye screening for their patients, rehabilitation services for the visually handicapped based both in hospital and the community, and establishing networks with primary care partners to provide basic and step-down eye care in the community.

At the same time, we maintain a strong emphasis on education - striving to train a good cadre of ophthalmologists for the future; and research – developing new technology for diagnosis and treatment.

Our aim is to provide the best care for our patients. The care that best meets their needs. And increasingly, we hope to do this in partnership with primary care partners.

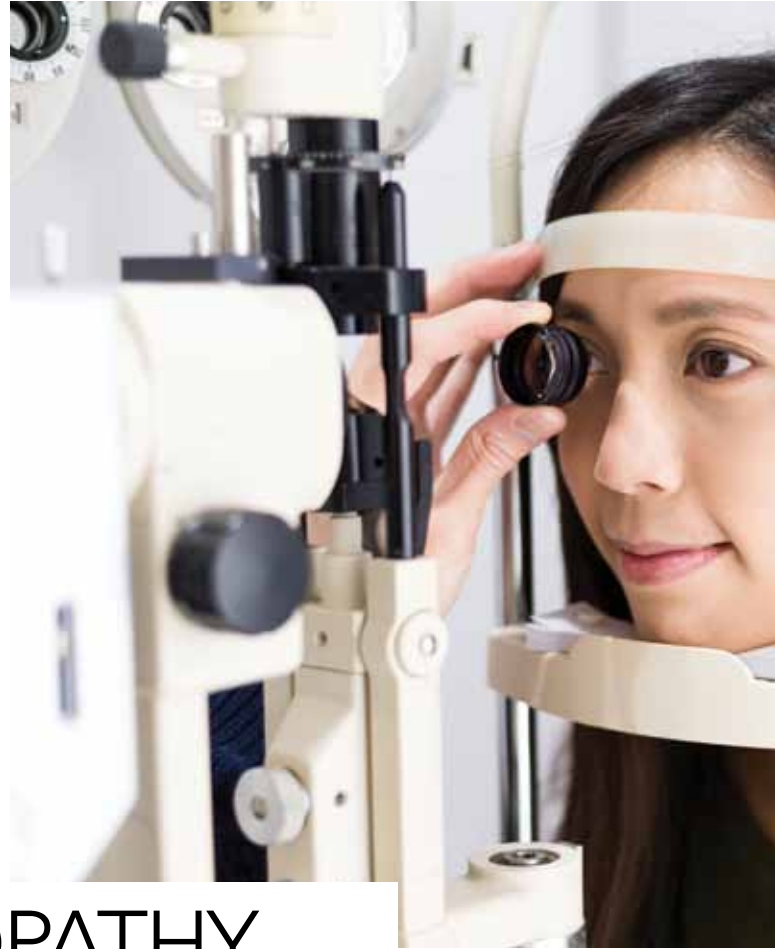

Associate Professor Paul Chew (left) & Professor Vivian Balakrishnan, Minister for Foreign Affairs (right). Associate Professor Paul Chew is the inventor of the Cyclo G6 Glaucoma TCP Micropulse Laser.

## HEALTH BURDEN OF DIABETES RETINOPATHY

Diabetes mellitus is a global epidemic with profound morbidity<sup>[1]</sup>. Complications arising from diabetes are divided into macrovascular (e.g. cardiovascular disease and stroke) or microvascular (e.g. diabetic retinopathy and kidney disease) in nature. Diabetic retinopathy (DR) is a leading cause of vision loss, particularly in the working population and the elderly<sup>[2,3]</sup>, severely impairing their quality of life and posing a significant health care burden for the society.

Diabetic retinopathy can progress from mild, non-proliferative to proliferative disease, whereby abnormal neovascularization occurs. This can result in sight-threatening vitreous haemorrhage and eventually tractional retinal detachment. Concurrently, at any stage of retinopathy, diabetic macular oedema (DME) can also occur due to exudation of lipids and fluid at the macula.



# DIABETIC RETINOPATHY – SCREENING IN THE COMMUNITY AND UPDATES IN LATEST MANAGEMENT GUIDELINES

30% of diabetic patients have DR, of which 5-10% may have sight-threatening stages of proliferative DR (PDR) and DME<sup>[4]</sup>. Lifetime risk of DR in patients with type 2 diabetes is 50-60%, and up to 90% in patients with type 1 diabetes<sup>[5]</sup>.

### IMPORTANCE OF SCREENING – THE ROLE OF A GENERAL PRACTITIONER (GP)

From a public health perspective, it is crucial to have regular population-based screening of diabetic patients by digital retinal photography. This would allow the identification of patients with DR and facilitate early intervention<sup>[6,7]</sup>. Studies have shown that systemic, national screening programmes can reduce blindness from diabetes by 30-50%, which translates to a 10% reduction of blindness in working adults<sup>[8]</sup>. The introduction of digital retinal photography without the need for pharmacological pupil

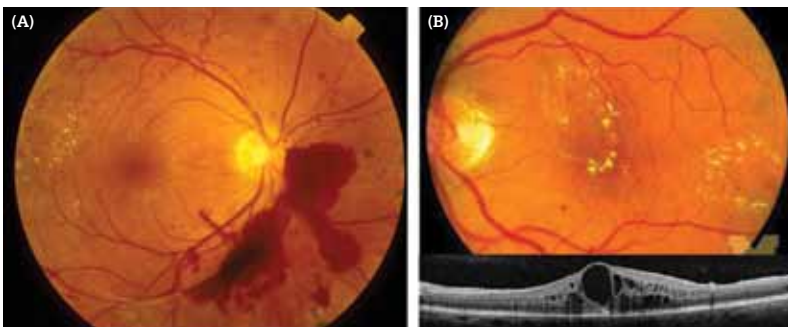
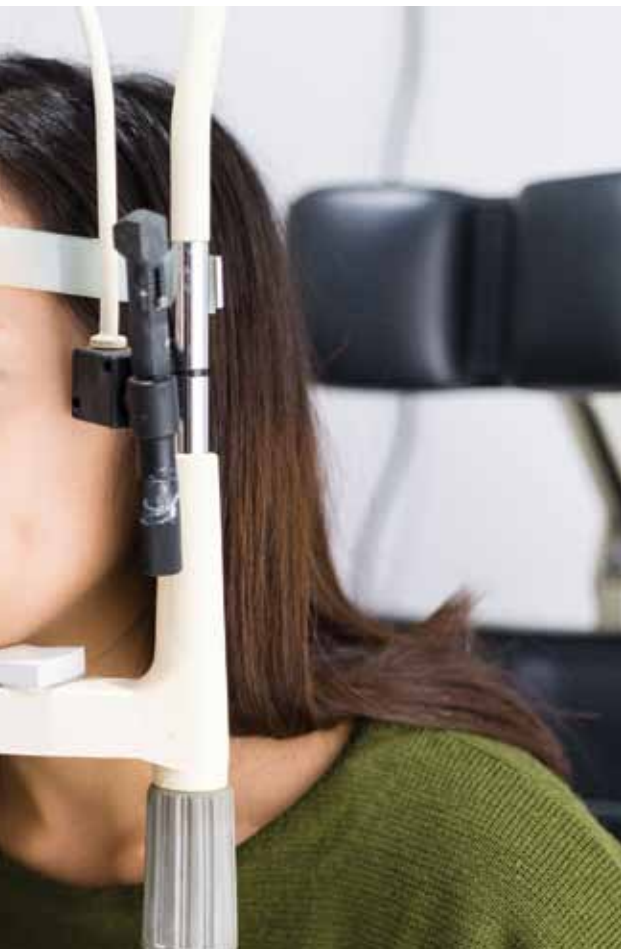

Figure 1: (A) Fundus picture of the right eye with proliferative diabetic retinopathy. Note the presence of neovascularisation in the superior arcades and inferior-nasal to the disc, in addition to the presence of vitreous haemorrhage. (B) Fundus picture and optical coherence tomography (OCT) image of the left eye showing diabetic macular oedema. Note the presence of exudates and microaneurysms involving the fovea in the fundus picture, and presence of intra-retinal fluid on the OCT.



**DIABETIC RETINOPATHY (DR) IS A LEADING CAUSE OF VISION LOSS, PARTICULARLY IN THE WORKING POPULATION AND THE ELDERLY, SEVERELY IMPAIRING THEIR QUALITY OF LIFE AND POSING A SIGNIFICANT HEALTH CARE BURDEN FOR THE SOCIETY.**

**STUDIES HAVE SHOWN THAT SYSTEMIC, NATIONAL SCREENING PROGRAMMES CAN REDUCE BLINDNESS FROM DIABETES BY 30-50%, TRANSLATING TO A 10% REDUCTION OF BLINDNESS IN WORKING ADULTS.**

of standardised protocol and high over-referral rates to tertiary eye care. To address these issues, the Singapore Integrated Diabetic Retinopathy Programme (SiDRP) was implemented in phases since 2010, as a comprehensive screening programme based on “real-time” assessment of DR from photographs by a centralised team of trained and accredited technicians, supported by a national tele-ophthalmology IT infrastructure. Patient’s retinal photographs are graded within an hour, allowing immediate feedback on DR status during the same primary care visit, with a referral to an ophthalmologist if necessary.

Alternatively, at NUH Department of Ophthalmology, we also provide a fundus photo based diabetic screening service, whereby any abnormalities detected on a fundus photo will be promptly attended to by our in-house ophthalmology specialists on the same day.

dilation (non-mydriatic retinal photography) and the adoption of telemedicine have facilitated large-scale screening in various developed and developing countries. In Singapore, most of our polyclinics provide yearly diabetic retinopathy fundus screening. However, some of the limitations faced in the traditional DR screening programme include delay in diagnosis, inconsistencies in grading outcomes due to lack



**Dr Su Xinyi**

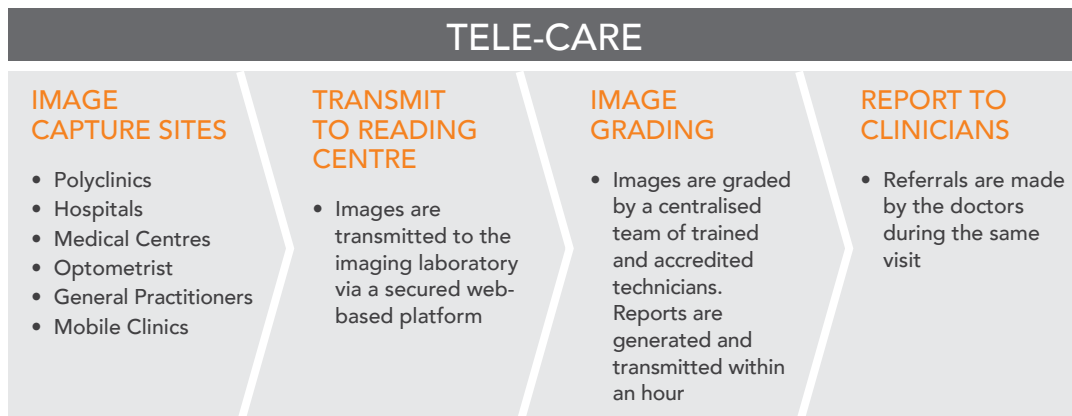
Associate Consultant,  
Department of  
Ophthalmology

As an A\*STAR scholar, Dr Su undertook her undergraduate medical degree and PhD training at the University of Cambridge, United Kingdom.

She completed her ophthalmology residency training at NUH in June 2016.

Being a clinician scientist, she holds an assistant professorship (tenured-track) at NUS, is a junior investigator at the Institute of Molecular Biology (IMCB), A\*STAR, and is also a clinical research fellow at Singapore Eye Research Institute (SERI). Her research focuses on the retina, particularly in (1) understanding the pathophysiology of diabetic retinopathy, in (2) developing novel drug delivery methods for retinal diseases such as for diabetic macular oedema and (3) developing novel materials for vitreous substitutes.

**SiDRP WORKFLOW**



**IMPORTANCE OF BLOOD GLUCOSE, BLOOD PRESSURE AND BLOOD PRESSURE CONTROL IN MANAGEMENT OF DR**

It is well-established in clinical trials that the risk of developing and hastening the progression of DR can be reduced by tight glucose and blood pressure control<sup>[9,10]</sup>. Interestingly, the benefits of early intensive glycemic control can be long-lasting (metabolic memory). On the contrary, tight blood control pressure (target <150/85mmHg) requires ongoing and long-term maintenance, with no sustainable benefits (no “memory”). Certain blood pressure lowering medications, particularly those that target the renin-angiotensin system, such as lisinopril (an angiotensin-converting enzyme inhibitor) and candesartan (angiotensin receptor blockade), exert additional beneficial actions such as reducing the risk of proliferative DR progression by 80%<sup>[11,12,13]</sup>. Although lipid control has been linked to DR, the effects of statin therapy on DR have been inconsistent<sup>[14]</sup>. The strongest evidence thus far suggests that fenofibrates reduce the risk of vision-threatening DR in T2DM<sup>[15]</sup>.

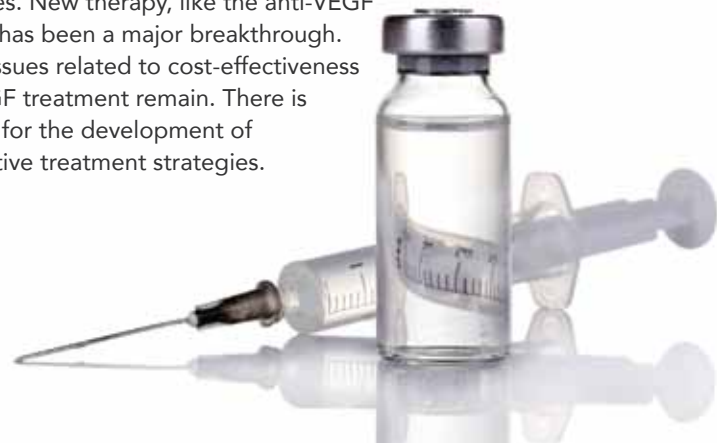**OPHTHALMIC MANAGEMENT OF DIABETIC MACULAR OEDEMA (DME) AND PROLIFERATIVE DIABETIC RETINOPATHY (PDR)**

Angiogenesis is a key underlying pathological pathway in both DME and PDR. Thus, the introduction of anti-vascular endothelial growth factor (anti-VEGF) agents in the 2000s, coupled with non-invasive imaging in the form of optical coherence tomography (OCT), has revolutionised the management of DME, allowing gain of vision<sup>[16,17]</sup>. This is unlike laser photocoagulation, the traditional gold standard treatment, which does not improve vision.

There are three commonly used anti-VEGF agents: ranibizumab, bevacizumab and aflibercept. A recent 12 month study performed by the DRCRnet, comparing head-to-head the relative efficacy and safety of all three agents, showed that all three agents improved vision in patients who have foveal involving DME<sup>[18]</sup>. However, aflibercept was more effective in improving vision in eyes with poorer initial vision.

Recent clinical trials have also shown that anti-VEGF therapy is useful for the treatment of proliferative DR. Intravitreal Ranibizumab is non-inferior compared to the gold standard treatment of pan-retinal laser photocoagulation. However, the need for patients’ compliance to monthly reviews and injections has cast doubts over its practicality compared to pan-retinal photo-coagulation (PRP) – a once off treatment<sup>[19]</sup>.

In conclusion, DR is an increasingly common global clinical and public health condition that poses a significant healthcare burden. In Singapore, we are fortunate to have very robust DR screening programmes. New therapy, like the anti-VEGF treatment, has been a major breakthrough. However, issues related to cost-effectiveness of anti-VEGF treatment remain. There is still a need for the development of more effective treatment strategies.



**References:**

[1] Shaw, J. E., Sicree, R. A. & Zimmet, P. Z. Global estimates of the prevalence of diabetes for 2010 and 2030. *Diabetes Res. Clin. Pract.* 87, 4–14 (2010).

[2] Antonetti, D. A., Klein, R. & Gardner, T. W. Diabetic retinopathy. *N. Engl. J. Med.* 366, 1227–1239 (2012).

[3] Cheung, N., Mitchell, P. & Wong, T. Y. Diabetic retinopathy. *Lancet* 376, 124–136 (2010).

[4] Zhang, X. et al. Prevalence of diabetic retinopathy in the United States, 2005–2008. *JAMA* 304, 649–656 (2010).

[5] Klein, R., Klein, B. E., Moss, S. E., Davis, M. D. & DeMets, D. L. The Wisconsin epidemiologic study of diabetic retinopathy. III. Prevalence and risk of diabetic retinopathy when age at diagnosis is 30 or more years. *Arch. Ophthalmol.* 102, 527–532 (1984).

[6] James, M., Turner, D. A., Broadbent, D. M., Vora, J. & Harding, S. P. Cost effectiveness analysis of screening for sight threatening diabetic eye disease. *BMJ* 320, 1627–1631 (2000). 22. Shi, L. et al.

[7] Telemedicine for detecting diabetic retinopathy: a systematic review and meta-analysis. *Br. J. Ophthalmol.* 99, 823–831 (2015)

[8] Rohan, T. E., Frost, C. D. & Wald, N. J. Prevention of blindness by screening for diabetic retinopathy: a quantitative assessment. *BMJ* 299, 1198–1201 (1989).

[9] The Diabetes Control and Complications Trial Research Group. The effect of intensive treatment of diabetes on the development and progression of long-term complications in insulin-dependent diabetes mellitus. *N. Engl. J. Med.* 329, 977–986 (1993).

[10] UK Prospective Diabetes Study (UKPDS) Group. Intensive blood-glucose control with sulphonylureas or insulin compared with conventional treatment and risk of complications in patients with type 2 diabetes (UKPDS 33). *Lancet* 352, 837–853 (1998).

[11] Tripathi, K. EUCLID study. *Lancet* 350, 1102–1103 (1997).

[12] Chaturvedi, N. et al. Effect of candesartan on prevention (DIRECT-Prevent 1) and progression (DIRECT-Protect 1) of retinopathy in type 1 diabetes: randomised, placebo-controlled trials. *Lancet* 372, 1394–1402 (2008).

[13] Sjolie, A. K. et al. Effect of candesartan on progression and regression of retinopathy in type 2 diabetes (DIRECT-Protect 2): a randomised placebo-controlled trial. *Lancet* 372, 1385–1393 (2008).

[14] Lim, L. S. & Wong, T. Y. Lipids and diabetic retinopathy. *Expert Opin. Biol. Ther.* 12, 93–105 (2012).

[15] The Diabetes Control and Complications Trial/Epidemiology of Diabetes Interventions and Complications Research Group. Retinopathy and nephropathy in patients with type 1 diabetes four years after a trial of intensive therapy. *N. Engl. J. Med.* 342, 381–389 (2000).

[16] Frank, R. N. Diabetic retinopathy. *N. Engl. J. Med.* 350, 48–58 (2004).

[17] Mitchell, P. & Wong, T. Y. Management paradigms for diabetic macular edema. *Am. J. Ophthalmol.* 157, 505–513 e1–e8 (2014).

[18] Aiello, L. P. et al. Vascular endothelial growth factor in ocular fluid of patients with diabetic retinopathy and other retinal disorders. *N. Engl. J. Med.* 331, 1480–1487 (1994)

[19] Writing Committee for the Diabetic Retinopathy Clinical Research Network. Panretinal photocoagulation versus intravitreal ranibizumab for proliferative diabetic retinopathy: A randomized clinical trial. *JAMA* 314, 2137–2146 (2015)

# STRABISMUS

**S**trabismus is a condition that causes an adult or child's eyes to point in different directions.

Measuring the ocular deviation can be done by the Hirschberg light reflex test. A light torch held in front of examiner and light is directed into patient's eyes. A normal reflex is a slight symmetrical nasal displacement of 5 degrees.

The consequence of acquired strabismus is diplopia/double vision. Before the age of six, there is cortical suppression of image from the

deviated eye, leading to strabismic amblyopia and a loss of binocular fusion and stereopsis.

There are several possible causes of strabismus, including weak eye muscles, heredity, cataract, and nerve conditions. Persons with the below dangerous effects of strabismus will need to be urgently referred:

1. **Acquired strabismus**
2. **Diplopia**
3. **Limited eye movements**
4. **Ptosis or other neurological signs**
5. **Poor vision**
6. **Abnormal red reflex**

Treatment may include a combination of patching, eye glasses, eye drops, eye exercises, and surgery. Surgery is only recommended if patching or eye glasses do not work. Strabismus surgery involves tightening the weak muscles and/or loosening the stronger ones so that the eyes are positioned better. During the operation, the surgeon will not cut the skin around the eye, take the eye out of its socket, or use any lasers. Special absorbable stitches are used to hold the eye muscles in their new position.

**THERE ARE SEVERAL POSSIBLE CAUSES OF STRABISMUS, INCLUDING WEAK EYE MUSCLES, HEREDITY, CATARACT, AND NERVE CONDITIONS.**

**THE CONSEQUENCE OF ACQUIRED STRABISMUS IS DIPLOPIA/DOUBLE VISION.**

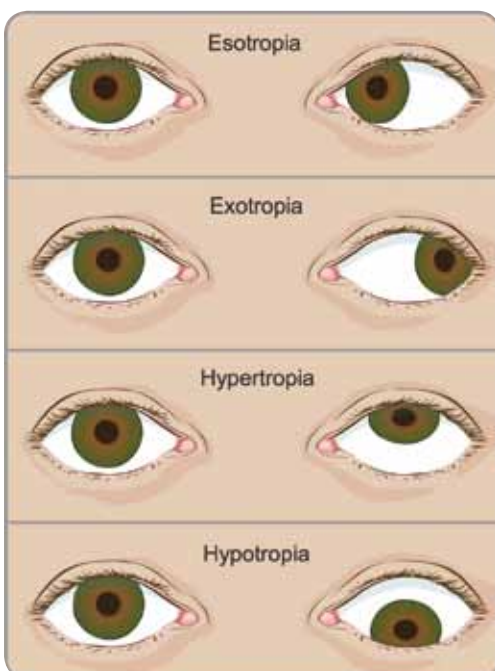


Figure 1: Forms of strabismus.



## Dr Cheryl Ngo

Head of Paediatric Ophthalmology and Strabismus  
Research Director  
Consultant, Department of Ophthalmology

Dr Ngo obtained her medical degree from NUS and was awarded the Singapore Medical Association Medal for MBBS and the Yeoh Khuan Joo Gold Medal for surgery in 2005. She completed her specialist ophthalmology training in Singapore, and holds a Master of Medicine (Ophthalmology), Singapore. She is also currently a fellow of the Royal College of Surgeons of Edinburgh. Dr Ngo was awarded the Academic Medicine Development Award FY2013 and completed a prestigious subspecialty fellowship training at the Hospital for Sick Children, Toronto, Canada. She is proficient in the management of complex strabismus cases, retinoblastoma, retinopathy of prematurity, paediatric cataract, glaucoma and neuro-ophthalmology cases, as well as adult cataracts.

A 65-year-old lady was presented to her family physician with blurring of vision in the left eye. On further questioning, she revealed that she only noticed three days ago that something was blocking the centre of her vision in the left eye. There was no associated pain and the patient also did not experience any floaters or flashes prior to this.

Her visual acuity was found to be 6/45 in the affected eye and the pupils constricted briskly when a light was shone using a pen torch. An attempt was made to look at the retina with a direct ophthalmoscope, however the pupil was only 3mm in diameter as is common in the elderly. Only a glimpse of the optic nerve was seen, which appeared unremarkable.

At this point, in view of the recent sharp decline in visual acuity of the left eye, an early referral was made to the ophthalmologist and the patient was seen the next day.

This is a common presentation of a patient with a recent onset of painless blurring of vision. Possible causes for this include retinal detachment, vitreous haemorrhage (especially if the patient is a poorly controlled diabetic), an acute sub-retinal bleed due to wet age-related macular degeneration or vascular causes such as a retinal vein occlusion. All these conditions require an early referral to an ophthalmologist for further management.

At the ophthalmologist, a dilated fundus examination revealed the following picture (Figure 1). The patient was diagnosed with wet age-related macular degeneration.

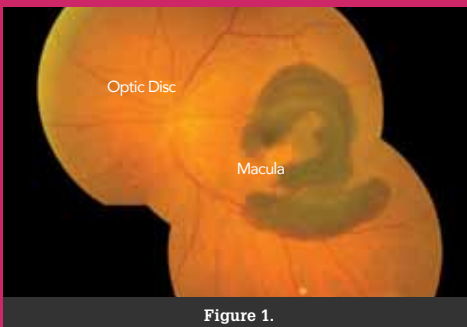


Figure 1.

# AGE-RELATED MACULAR DEGENERATION

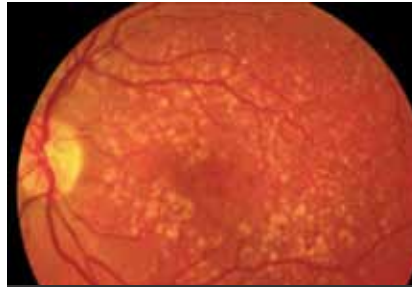


Figure 2: Dry AMD with drusen.

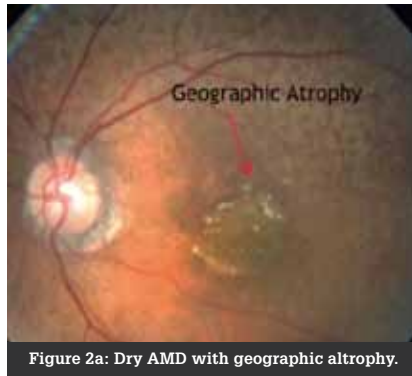


Figure 2a: Dry AMD with geographic atrophy.




Figure 3.

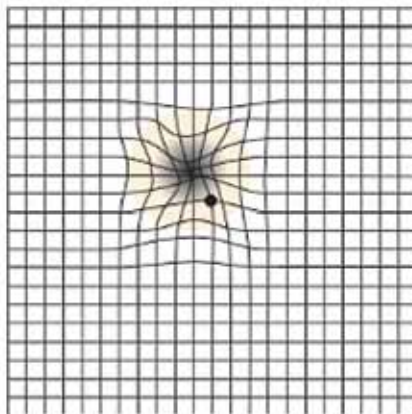


Figure 3a.

**A**ge-related macular degeneration (AMD or ARMD) is an eye condition that involves the macula. The macula is the area of the retina that is responsible for central vision and the ability to see fine detail. AMD is classified as either dry (non-neovascular) or wet (neovascular).

## DRY AMD

Patients with dry AMD can have normal vision in the early stages. Yellowish deposits called drusen (Figure 2) accumulate in the macula and vision deterioration may occur gradually over years as the macula deteriorates and the tissue atrophies. In the late stage where there is geographic atrophy of the macula, central visual loss can be severe (Figure 2a).

## WET AMD

In about 10% of cases, dry AMD progresses to the wet form, where there is growth of an abnormal network of vessels beneath the retina (also known as choroidal neovascularisation or CNV). Haemorrhage and leakage of fluid from these abnormal vessels lead to a sudden drop in vision. If not treated early, this can lead to scarring and severe central vision loss.

A useful screening test for central vision is the Amsler chart. (Figure 3) The patient tests each eye individually by looking at the dot in the centre of the grid placed 30cm away. Patients with macula problems will see the straight lines as wavy or blurred with dark spots at the centre (Figure 3a).

## WORKUP

In patients with wet AMD, fluorescein angiography is performed to identify the abnormal blood vessels (CNV) to help make the diagnosis. This identifies the location of the CNV and shows leakage from these abnormal vessels. Optical coherence tomography (OCT) is also performed which takes cross sectional images of the retina allowing the amount





of leakage and swelling to be quantified. The OCT machine takes only a few seconds to acquire the image and is non-contact, i.e. it does not come in contact with the patient's eye. This aids in the management and follow up of the patient's response to treatment.

#### MANAGEMENT

The risk factors for AMD include ageing, a family history of AMD, obesity and inactivity, smoking and high blood pressure. Encouraging a healthy lifestyle with adequate exercise, cessation of smoking and a diet of more green leafy vegetables and foods rich in omega-3 fatty acids such as salmon can be beneficial.

Nutritional supplements containing vitamin C and E, lutein and zeaxanthin can be easily obtained over the counter at pharmacies and may reduce the risk of dry AMD progressing to wet AMD.

For wet AMD, the standard of care is to give intra-vitreous injections of anti-VEGF (vascular endothelial growth factor) in the affected eye. This procedure is done in the clinic procedure room under topical anaesthetic eye drops. There are currently three main anti-VEGF drugs on the market, namely Bevacizumab, Ranibizumab and Aflibercept. All three drugs have been shown to be effective in treating wet AMD. As there is a very small risk of acute thromboembolic events occurring with the use of anti-VEGFs, the drug is generally not given to patients

### THE MACULA IS THE AREA OF THE RETINA THAT IS RESPONSIBLE FOR CENTRAL VISION AND THE ABILITY TO SEE FINE DETAIL.

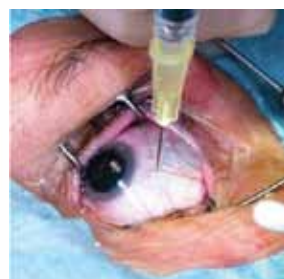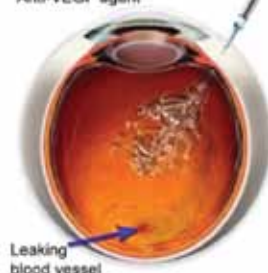
### THE RISK FACTORS FOR AMD INCLUDE AGEING, A FAMILY HISTORY OF AMD, OBESITY AND INACTIVITY, SMOKING AND HIGH BLOOD PRESSURE.

with a recent history of myocardial infarction or stroke.

Laser or photodynamic therapy is also a treatment option that may complement the use of anti-VEGF injections.

Patients undergoing treatment for AMD must understand that the disease is chronic and will require multiple injections which are initially given monthly. The frequency of injections generally decreases with time and is determined by the response of the individual to the treatment.

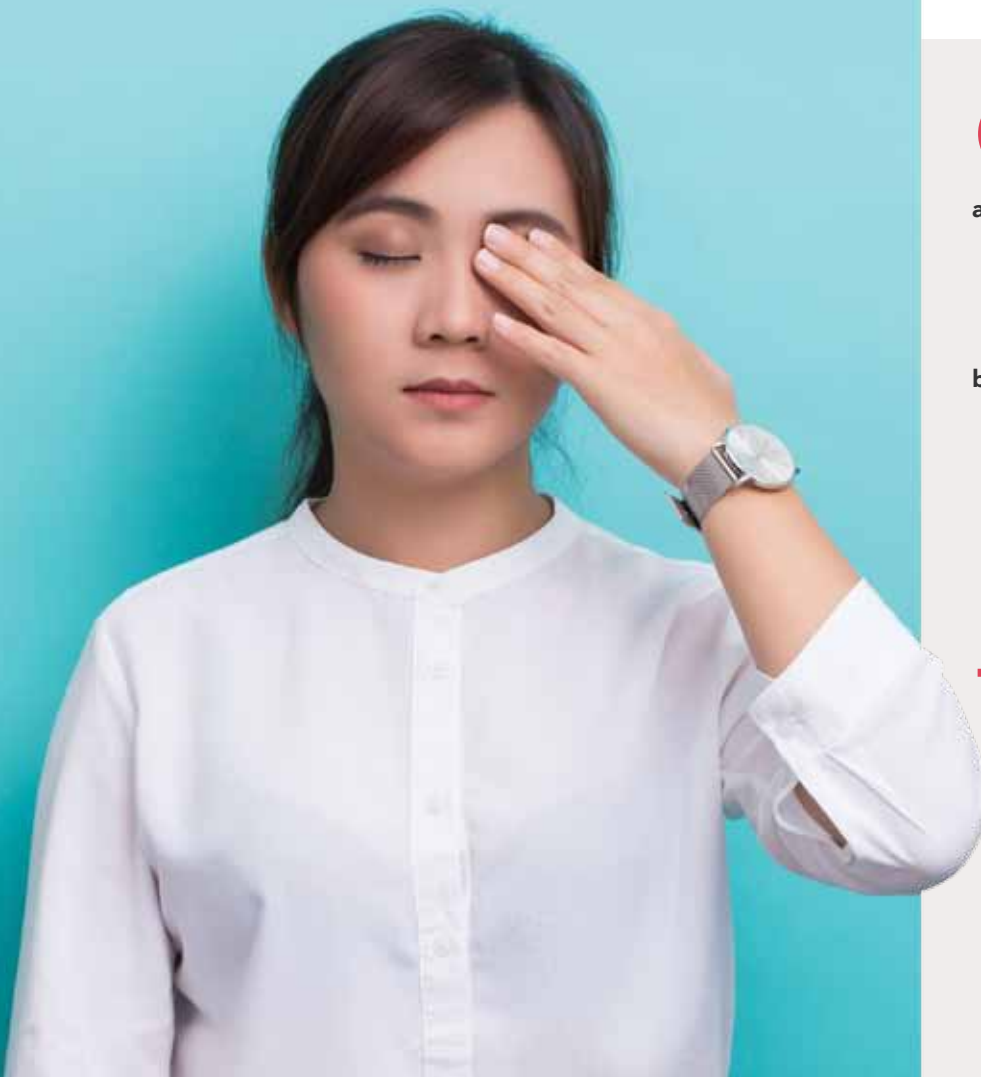Intra-vitreous injection of Anti-VEGF agent



#### Dr Paul Zhao

Consultant, Department of Ophthalmology

Dr Zhao graduated from the National University of Singapore in 2002. He underwent basic and advanced specialty training in ophthalmology in Singapore before pursuing his retina fellowship under Professor David Wong at Queen Mary Hospital, Hong Kong. Dr Zhao's field of subspecialisation is in vitreoretinal disease and he performs retina surgery for conditions such as retinal detachment, macular holes and epiretinal membranes, diabetic eye disease (tractional retinal detachment, vitreous haemorrhage) and vitreomacular traction. A significant proportion of his clinical work also involves the medical management of patients with age-related macular degeneration, retinal vascular disorders, diabetic eye disease, retinal dystrophies and intraocular infections. He also performs cataract surgery and is trained in the latest technology using femtosecond laser assisted cataract surgery and the use of premium intraocular lenses for correction of astigmatism and presbyopia.



## 1 WHAT ARE FLOATERS?

- a. Floaters are perceived as specks, swirls or dusts, which move within the eye, within our field of vision. They manifest in various forms, for example, as cobwebs, circles, lines, dots or swirls.
- b. Floaters arise from condensation of the collagen within the vitreous, casting a shadow on the retina. The vitreous is a transparent body of gel-like fluid that fills the eye. It lies just in front of the retina, which is responsible for capturing light and transmitting electrical signals to the brain, enabling us to see.

## 2 WHAT ARE FLASHES?

- a. Flashes are a form of positive phenomenon, resulting from the vitreous tugging on the retina. They are perceived as streaks of light emanating from within the eye. Flashes typically manifest in the corner of the eye and may be more apparent at night.

# FLOATERS, FLASHES, POSTERIOR VITREOUS DETACHMENT AND RETINAL DETACHMENT

## 3 WHAT IS POSTERIOR VITREOUS DETACHMENT (PVD)?

- a. Posterior vitreous detachment (PVD) occurs when the vitreous undergoes liquefaction. The gel shrinks and pulls itself away from the retina. This is a physiological consequence and the most common cause of floaters.
- b. During the physical separation of the vitreous from the retina to which it is tightly adhered, the gel may inadvertently pull off an area of the retina resulting in a retinal tear(s). Retinal tear(s) can potentially lead to retinal detachment if it is not detected promptly and adequately treated.

## 4 HOW DOES A RETINAL TEAR LEAD TO RETINAL DETACHMENT?

- a. The liquefied vitreous enters the retinal tear(s) thereby lifting the retina off from its original position.
- b. Retinal detachments require surgical intervention. They can be broadly categorised into macula-on or macula-off. Cases where the macula (central portion of the retina governing central visual function) is still attached, surgical intervention is emergent in order to minimise vision loss. Cases whereby the macula is 'off' will also require early intervention in order to restore vision.

5

**CAUTION****WHAT ARE THE RED FLAGS SYMPTOMS FOR RETINAL DETACHMENT?**

- A sudden increase in the number or shower of floaters.
- A sudden appearance of flashes, particularly if there are continuous bouts of flashes.
- A sudden onset of painless, blurred vision.
- A sudden shadow over the field of vision spreading from the side towards the centre.

6

**WHO IS AT RISK OF RETINAL DETACHMENT?**

- Someone who is short-sighted (myopic).
- History of trauma to the eye.
- History of eye surgery e.g. cataract surgery.
- History of previous lasers e.g. previous retinal lasers, YAG capsulotomy (laser polishing of the posterior lens capsule post cataract surgery for posterior capsule opacification).

**WHEN SHOULD I REFER MY PATIENT FOR OPHTHALMIC EVALUATION?**

7

- Any patient with the red flag symptoms (listed in Point 5) should be referred for urgent formal assessment by an ophthalmologist.
- Any patient with new onset of floaters should be referred for early assessment by an ophthalmologist.

**WHAT ARE THE INTERVENTIONS FOR RETINAL TEARS AND RETINAL DETACHMENTS?**

8

- Retinal tears (with or without limited localised area of retinal detachment) may be treated with laser retinopexy. Laser retinopexy is a form of thermal laser that is applied around the tear and acts as a form of barrage to prevent vitreous from entering the tear.
- Retinal detachments require surgical intervention either in the form of scleral buckling procedure or vitrectomy.
- In all cases, the principles of retinal detachment surgery are:
  - Locate all the retinal breaks
  - Seal all the retinal breaks (laser or cryotherapy)
  - Drainage of subretinal fluid
  - Re-establish chorioretinal adhesion
- Scleral buckling procedure involves securing silicon explant onto the sclera (external wall of the eye) and follows the above surgical principles.
- Vitrectomy is a form of internal fixation and requires the creations of ports on the wall of the eyes (sclerostomies). Instruments are introduced into the eye via the sclerostomies and the vitrector (a.k.a. cutter) is used to trim the vitreous down to the retina. The retina is then flattened back into its original position and held in place by injection of gas or silicone oil.

**Dr Chan Hwei Wuen**

Associate Consultant,  
Department of  
Ophthalmology

Dr Chan received her formal medical training at the University College London (UCL) and her first exposure to ophthalmology was during her stint at Moorfields Eye Hospital as a student, which fuelled her interest to pursue a career in this specialty. She completed her residency training in Ophthalmology at the National University Hospital, Singapore, in June 2016. She is a member of the Royal College of Ophthalmologists (UK) and is currently pursuing her fellowship training in medical retina and vitreoretinal surgery.

Dr Chan also has a keen interest in visual electrophysiology and complex cataract surgery. She is proficient in the management of adult cataracts and is trained in femtosecond laser assisted cataract surgery.

During her residency training, Dr Chan served as the Chief Resident from 2014-2015. She is actively involved in undergraduate and postgraduate teaching and was awarded the NUS MedSoc Outstanding Tutor Award. Dr Chan holds a joint appointment on the NUS Clinical Faculty Scheme.



## SENIORS' EYE REHABILITATION PROGRAMME

### HELPING SENIORS WITH LOW VISION LIVE INDEPENDENTLY

The NUH Vision Care Services was developed to address the visual issues of an ageing population and the increasing prevalence of visual impairment from age-related eye conditions. Poor vision may lead to falls and its dire consequences (e.g. hip fracture, loss of mobility resulting in functional decline) in this vulnerable group. Beyond visual consequences, the impact of low vision is complex. Low vision has functional, psycho-social, emotional, economic consequences that impact the individual's or the caregiver's quality of life. In other words, low vision is both a clinical condition and lived experience.

NUH Vision Care Services comprise of the Eye Care for Empowered Community Programme (EC2) and the Seniors' Eye Rehabilitation Programme (SEER). Its objectives are to identify seniors with poor or low vision to provide early intervention in the form of treatment and to teach them to function safely within the limitations of their remaining vision.

Low vision is defined by the World Health Organization as visual impairment that remains even after treatment and/or standard refractive correction of less than 6/18 to light perception or a visual field of less than 10 degrees from the point of fixation. Such individuals are still potentially able to use vision for the planning and/or execution of a task.

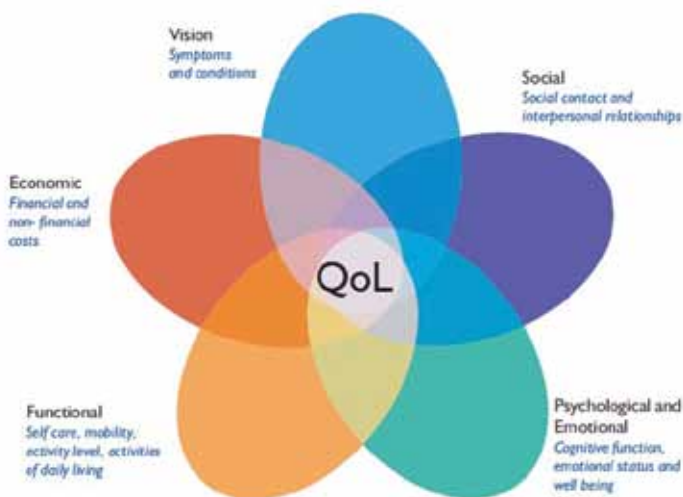


Figure 1. Multidimensional impact of low vision on quality of life (QoL).

The common causes of low vision are glaucoma, age-related macular degeneration (AMD), diabetic retinopathy and vision loss from neurological conditions. These conditions limit the eye's ability to function normally, and impact vision differently. For instance, advanced glaucoma leads to constricted visual fields or 'tunnel vision', AMD causes central field loss or a 'central blind spot', diabetic retinopathy may result in 'blotchy vision', and neurological conditions in peripheral field loss or hemianopia.

## LOW VISION IN CONTEXT: SOME DAY-TO-DAY FUNCTIONAL DIFFICULTIES

A person with the below stated conditions may encounter difficulties in the following tasks/functions:

### AMD and central visual loss

- recognising people, faces, objects or actions
- reading posters or signs
- having independent mobility
- understanding non-verbal communication

### Diabetic retinopathy and blotchy vision

- reading newspapers and documents
- with personal care and hygiene
- preparing food and eating
- matching clothes

### Severe glaucoma and constricted visual fields functioning in poor light

- finding objects
- having independent mobility
- navigating steps or curbs

## AN INTEGRATED APPROACH TO CARE

The Eye Care for Empowered Community Programme (EC2) was developed in 2015 to address undetected eye problems amongst the elderly clients (term for an elderly individual in a community set-up) or patients residing in elder-care institutions which include day care facilities, senior's activity centres, day care rehabilitation set-ups and nursing homes. Clients and patients detected to have previously undiagnosed eye

## LOW VISION IS BOTH A CLINICAL CONDITION AND LIVED EXPERIENCE.

### THE COMMON CAUSES OF LOW VISION ARE GLAUCOMA, AGE- RELATED MACULAR DEGENERATION (AMD), DIABETIC RETINOPATHY AND VISION LOSS FROM NEUROLOGICAL CONDITIONS.

### THE SEER PROGRAMME TAKES AN INTEGRATED, MULTIPRONGED APPROACH TO END-TO-END CARE THAT ENCOMPASSES A VARIETY OF SERVICES THAT ADDRESS THE NEEDS OF THE 'WHOLE PERSON'.

ailments are referred directly to various subspecialty services at the NUH Eye Surgery Centre, hence easing the process from diagnosis to early treatment. Nurses, nursing aids and care givers are also enrolled into a one-day eye care programme with the aim of increasing awareness of eye ailments in the elderly, and having basic skills such as visual acuity assessment, proper techniques in eye drop instillation, care of individuals with low vision and managing them in the immediate post-operative period.

The SEER Programme is a collaboration between NUH and the Agency for Integrated Care (AIC). Through a team-based multidisciplinary approach involving ophthalmologists, optometrists, occupational therapists, care coordinators and community-based services, the programme aims to help seniors with low vision to age-in-place in their homes and within the community through a customised visual rehabilitation programme. This programme ensures that safety issues are adequately addressed in seniors with low vision whilst encouraging them to continue to function as independently as possible within the limitations of their low vision.

The SEER Programme takes an integrated, multipronged approach in end-to-end care that encompasses a variety of services which



**Dr Dawn Lim  
Ka-Ann**

Consultant,  
Department of  
Ophthalmology

Dr Lim spent two years gaining further experience in various fields of medicine including dermatology and rheumatology, which culminated in her admission as a member into the Royal College of Physicians (MRCP, UK) prior to commencing formal ophthalmology training. An awardee of the esteemed Ministry of Health training scholarship, Dr Lim proceeded to complete her advanced specialist training in ophthalmology in mid-2014. During her training, she held the administrative appointment of Chief Resident from 2011 to 2012. She is currently undergoing further subspecialty fellowship training at the renowned Moorfields Eye Hospital NHS Foundation Trust, London, UK. Dr Lim holds several grants in research and vision-care related work. Active in research and education, she has co-authored scientific papers in peer-reviewed medical journals and several book chapters in ophthalmology texts. She has special interests in visual problems in the elderly, ocular inflammatory disorders, complex cataract surgery and the medical cum surgical management of primary and secondary glaucoma. She leads the NUH Vision Care Services.

addresses the needs of the 'whole person'. Such needs may include regaining independence, managing the home, taking care of personal needs, and participating in the community, work and leisure activities.

Upon identification by the treating ophthalmologists, patients are referred directly to the SEER Programme through a low vision care coordinator who facilitates the intake, and navigates the patient through various service points in the programme. Where necessary, the care coordinator would assist to connect patient with relevant social help services.

Optometrists assess visual functions and prescribe optical and adaptive aids to optimise residual usable vision. Depending on the need and activity, the optometrist may prescribe high-

powered reading glasses, hand-held magnifier or an electronic desktop magnifier. A range of optical aids may be prescribed for various tasks (Figure 2). The optometrist also advises on lighting and contrast enhancement to improve function (Figure 3).

Occupational therapists enable patients to perform valued occupations. In the SEER Programme, occupational therapists with unique training in low vision rehabilitation guide seniors in visual remediation skills. These include the use of adaptive aids, developing adaptive skills to remain independent at home, at work and in the community, and addressing personal needs such as self-care (Figure 4). In addition, home assessments and environmental modifications are made to create a safer home environment for the patient. Examples of interventions include placing tactile markings on electrical appliances such as an oven or water flask, designing a system to organise clothes and consolidation of medications (Figure 5) in affected individuals.

Other rehabilitation services for seniors with low vision include orientation and mobility training, counselling services and support groups. These services are provided by volunteer welfare organisations (VWOs) such as the Singapore Association of the Visually Handicapped and the Guide Dogs Association of the Blind. With the assistance of a care coordinator, seniors are connected with the necessary organisations that provide various aspects of help and care, ensuring that they do not fall through the gaps.

The SEER Programme also aims to build community capability in low vision rehabilitation. Under this initiative, NUH's occupational therapists have developed a programme to train community occupational therapists based

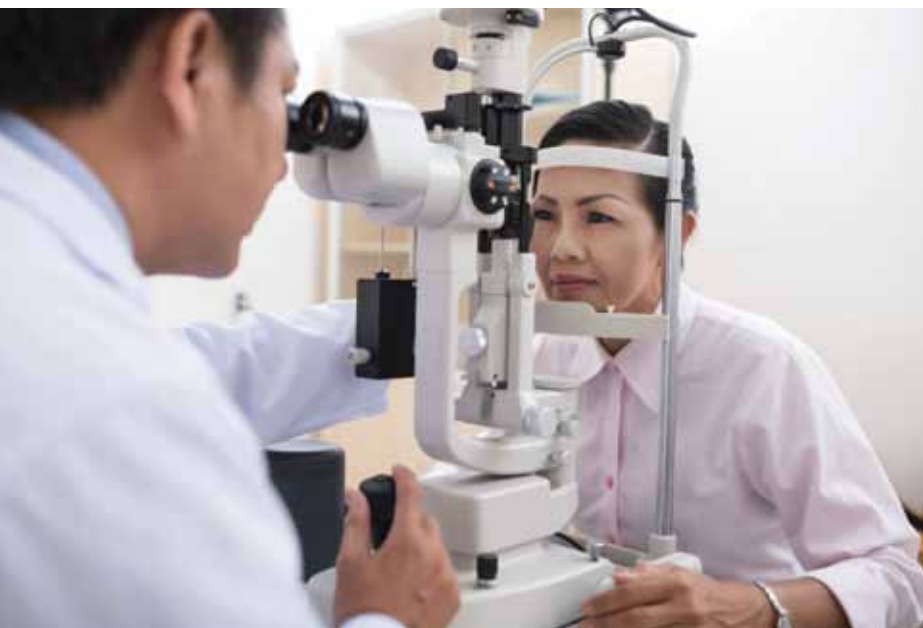

Figure 2: Optical low vision aids.



Figure 3: Task lighting to enhance reading.



Figure 4: A liquid indicator to facilitate pouring hot drinks.



Figure 5: Tactile markings on an oven for safe use.



in VWOs or community hospitals in low vision rehabilitation skills, with the aim of continuing care of these seniors within their homes or in step-down care facilities.

The SEER model bridges NUH Department of Ophthalmology with partners in community care settings in providing integrated and

holistic care for seniors with low vision. It is hoped that this model could be replicated to other regional health systems to provide early and appropriate care to seniors with low vision, so that they can seamlessly and safely transit from the point of diagnosis in the acute hospital-care setting, back to their homes and the community.



**Danial Bohan**


Senior Optometrist,  
Department of  
Ophthalmology

Danial Bohan has special interests in geriatric and low vision rehabilitative optometry. He co-developed the first multidisciplinary low vision rehabilitation model in a hospital setting in Singapore. Danial is also an Adjunct Instructor at the Yong Loo Lin School of Medicine, NUS and an Advisory Member of the World Health Organization's Low Vision Working Group for the Western Pacific Region. His research interests include psycho-social aspects of low vision, qualitative health research and patient outcomes in low vision rehabilitation. He is active in inter-professional medical education, and has written and presented extensively on low vision rehabilitation. He was awarded the NUH Teaching Excellence Award in 2016, and the Eye and Vision Health Award (Meritorious Service Award) in 2015. Danial graduated with an MSc from Anglia Ruskin, UK.


**REFERRAL CRITERIA TO THE SEER PROGRAMME**



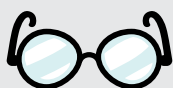Aged 50 years and above



Visual acuity of less than 6/18 with best correction after treatment; and/or



Visual field of less than 10 degrees



Known diagnosis of low vision



Per capita monthly income of no more than \$2,600

Family physicians who would like more information about the NUH Vision Care Services or SEER Programme can email us at [low\\_vision@nuhs.edu.sg](mailto:low_vision@nuhs.edu.sg).

# CATARACT TREATMENT AND MANAGEMENT

**C**ataract is an opacity in the lens which can block light causing blurred vision. No medical treatments have been shown to be effective in the prevention or treatment of cataract.

Extraction of cataract is one of the most common elective surgical procedures. The World Health Organization estimates the number will increase to 32 million by the year 2020<sup>1,2</sup>. Surgical treatment involves removing the lens and replacing it with an artificial lens. Over the past decades, there have been many changes in the surgical technique.

Two main types of surgical procedures are in common use throughout the world. The first procedure is phacoemulsification (phaco) and the second is extracapsular cataract extraction (ECCE). In most surgeries, an intraocular lens is inserted. Foldable lenses are generally used for the 2-3mm phaco incision, while non-foldable lenses are placed through the larger extracapsular incision. The small incision size used in phacoemulsification (2-3mm) often allows "sutureless" incision closure. ECCE utilises a larger incision (10-12mm) and therefore usually requires stitching.

The vast majority of our cataract operations are now done by phacoemulsification which uses ultrasound energy. The vibrating phacoemulsification instrument is introduced into the eye through the small wound. It causes emulsification (softening) of the cataractous lens which

**CATARACT SURGERY COMPLICATIONS ARE FEW, AND CATARACT SURGERY IS AMONG THE MOST COMMON AND MOST SUCCESSFUL SURGICAL PROCEDURES PERFORMED TODAY.**

**ELECTIVE CATARACT SURGERY IS PERFORMED AS A DAY/ AMBULATORY SURGERY, UNDER LOCAL OR TOPICAL ANAESTHESIA, ON ONE EYE AT A TIME.**

is aspirated out through the instrument at the same time. The capsule of the lens is left behind which then receives the artificial lens implant. The surgery is completed without any need for stitches.

Since 2012, NUH has started doing femtosecond laser assisted cataract surgery with good results. In laser cataract surgery, an advanced femtosecond laser replaces or assists the use of a hand-held surgical tool for the following steps in cataract surgery:

1. The corneal incision
2. The anterior capsulotomy
3. Lens and cataract fragmentation





Use of a laser can improve the precision, accuracy and reproducibility of each of these steps, potentially reducing risks and improving visual outcomes of cataract surgery.

Elective cataract surgery is performed as a day/ ambulatory surgery, under local or topical anaesthesia, on one eye at a time.

#### TYPES OF INTRAOCULAR LENS AVAILABLE

Artificial intraocular lenses, or IOLs, replace the eye's natural lens that is removed during cataract surgery.

Traditionally, a monofocal IOL is used. Cataract surgery with implantation of a traditional monofocal IOL, targeting distance vision, leaves most individuals dependent on some correction, usually spectacles, for near vision.

Unlike conventional "single vision" (monofocal) intraocular lenses (IOLs), multifocal IOLs are lens implants that are designed to help patients see at varying distances using different points of focus. The goal of a multifocal IOL is to provide functional vision at different distances to minimise the use of glasses. Although they might still prefer to wear glasses for prolonged reading, the vast majority of multifocal IOL patients experience freedom from glasses.

#### MULTIFOCAL TORIC LENSES

Multifocal toric lenses have the ability to correct astigmatic as well myopic or

hyperopic refractive errors. This is a major advancement as many patients who had astigmatism were previously unable to benefit from multifocal lens implantation because astigmatism will compromise the quality of vision that can be achieved in multifocal lenses.

Cataract surgery complications are few, and cataract surgery is among the most common and most successful surgical procedures performed today. One of the most common cataract surgery complications is a posterior capsule opacity (also called posterior capsule opacification or PCO). During cataract surgery, the natural lens is removed and replaced with an intraocular lens (IOL). Much of the thin clear membrane that surrounds the natural lens (called the lens capsule) is left intact during surgery and the IOL usually is implanted within it.

However, in about 20 percent of patients, the posterior portion of the capsule becomes hazy some time during cataract surgery recovery or even months later, causing posterior capsule opacification (PCO). PCO occurs because lens epithelial cells remaining after cataract surgery have grown on the capsule.

Fortunately, a YAG laser can treat posterior capsule opacity safely, effectively and painlessly. This procedure, known as YAG laser capsulotomy, often can be performed in the clinic.

Other complications include retinal detachment, posterior capsular rupture, corneal and macular swelling and endophthalmitis. It is usually possible to successfully treat complications that arise from cataract surgery with medication or further surgery. The majority of people have a good result from surgery and are happy with the improvement in their vision.



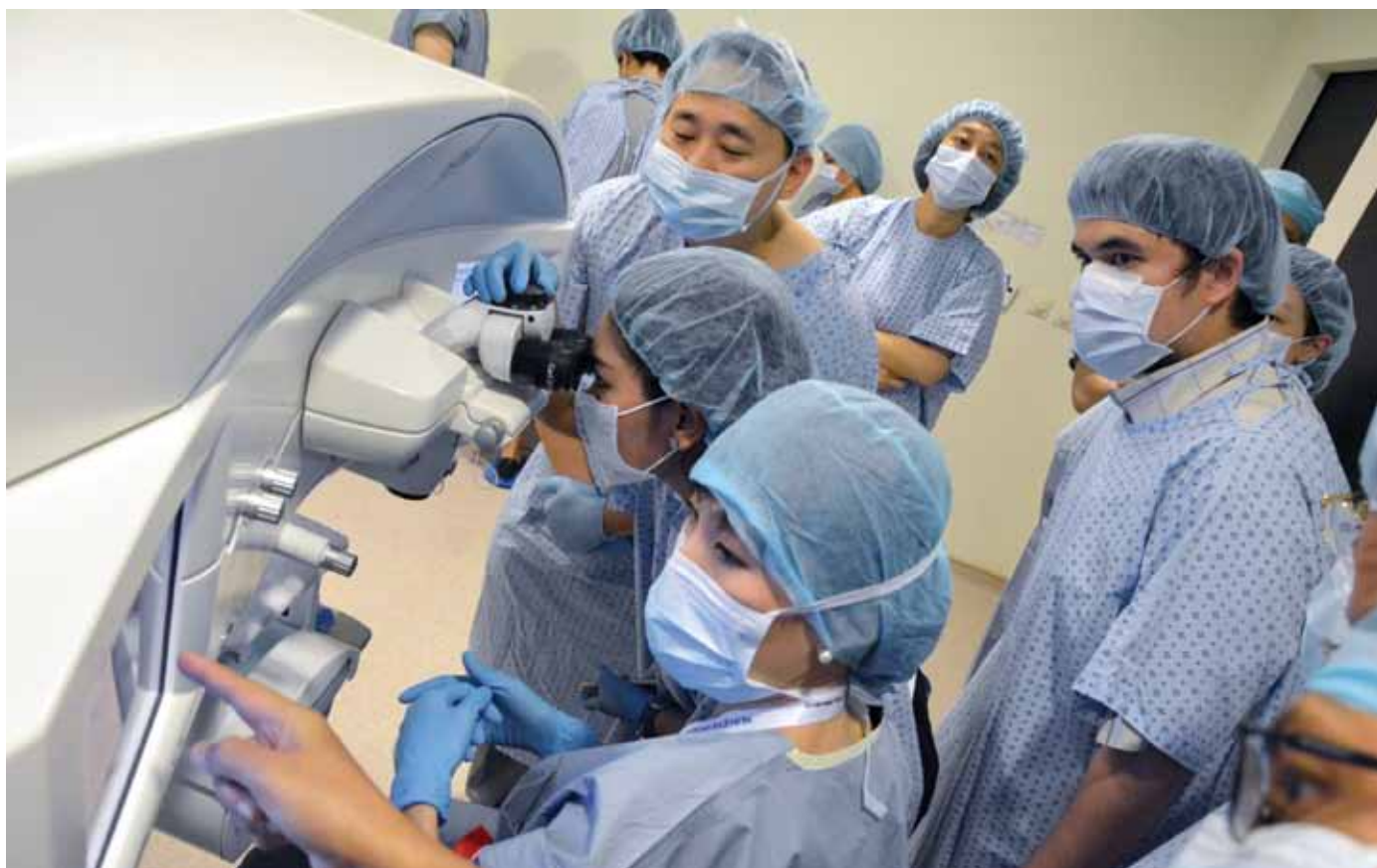**Dr Vivien Lim**

Consultant, Department of Ophthalmology

Dr Lim became a Member of the Royal College of Surgeons of Edinburgh and was awarded the Master of Medicine (Ophthalmology) by NUS in 2009. Upon completion of her residency in 2012, Dr Lim became a Fellow of the Academy of Medicine, Singapore (FAMS). She was awarded the Academic Medical Development Award in 2015 and she trained with the renowned refractive surgeon Professor Jesper Hjorddal in the University of Aarhus on SMILE, the latest generation of laser technique in refractive surgery. Her research interests are in refractive and cataract surgery. She is active in teaching medical students and ophthalmology residents, and is a faculty member at the Yong Loo Lin School of Medicine, NUS. She has vast experience with a broad range of cataract surgical techniques and new techniques such as femtosecond laser assisted cataract surgery and multifocal toric intraocular lens implantation. Her practice interests include general ophthalmology; adult cataract surgery; LASIK and refractive surgery.

#### References:

- [1] Trikha S, Turnbull AM, Morris RJ, Anderson DF, Hossain P. The journey to femtosecond laser-assisted cataract surgery: new beginnings or false dawn? *Eye* 2013; 27:461-473
- [2] Brian G, Taylor H. Cataract blindness – challenges for the 21st century. *Bull World Health Org* 2001; 79:249-256.



## EXTRAORDINARY SERVICE FOR AN ORDINARY PROBLEM

# NUH OPHTHALMOLOGY CATARACT SUITE

**T**he NUH Eye Surgery Centre is located on the 17<sup>th</sup> floor of the Medical Centre. The Centre offers a wide range of services and provides dedicated care and high quality treatment for all patients.

Cataracts, the most frequent condition seen in our clinics, are one of the most common causes of reversible vision loss affecting all individuals over the age of 50. Spectacles are useful for improving initial visual acuity. However, cataracts eventually become visually significant and surgical removal becomes the only available treatment.

From mid 2017, we will be launching our new Cataract Suite offering a streamlined service for those seeking cataract consultations – from

consultation till the completion of post-operative care. Housed in a tertiary-level medical centre, we provide holistic

care for each patient by teaming up our senior doctors, staff nurses and trained allied health professionals, who have easy access to other specialities in NUH.

### OUR GOALS

- Dedicated cataract clinic that provides seamless service for those seeking consultation for cataracts
- To provide patient experience and minimise movement for our patients
- To provide patient education and counselling regarding the various treatment options and available intraocular lens choices

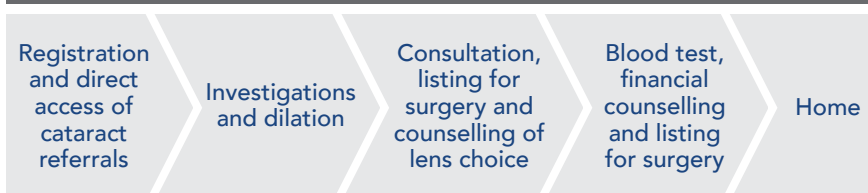The Cataract Suite was created with the intention of reducing physical movement and time spent by our visually impaired patients during a visit, some of whom may have other physical disabilities. Our staff are equipped with relevant skills to screen and pre-order appropriate investigations, and to provide counselling for our patients. Our team can converse fluently in various languages to cater to patients of different ethnic groups. To supplement our service, we have created new informative materials to ensure that our patients have adequate access to information pertaining to the choice of

## FEATURES OF OUR CATARACT SUITE

- Personalised care by our Cataract Team comprising of senior doctors, allied health and operating theatre staff
- Reduced waiting time for consultation and surgical listing
- Availability of a wide range of lens selection
- Minimal movement between investigations and consultation



## OUR WORKFLOW



**FROM MID 2017, WE WILL BE LAUNCHING OUR NEW CATARACT SUITE OFFERING A STREAMLINED SERVICE FOR THOSE SEEKING CATARACT CONSULTATIONS - FROM CONSULTATION TILL THE COMPLETION OF POST-OPERATIVE CARE.**

surgery, latest treatment options, and available types of intraocular lenses.

The success of surgery to many patients depends on their expected visual outcome, and we recognise the importance of using the latest available advanced equipment to optimise precision and visual outcomes. Our newly integrated cataract system allows for accurate intraocular lens calculation and direct transition of information to our surgical platform, reducing the potential risk of human errors that occur during the transcription of

information. Our image-guided surgical platform also helps to improve precision during toric intraocular lens implantation for astigmatic correction. Allied health members, operating theatre staff and doctors have attended workshops to hone their skills with the support of our industrial partners. Together with an ongoing audit process, we are confident that our patients will have a smooth journey and pleasant experience when they come to us to solve the most common ophthalmic surgical problem in Singapore.



**Dr Charmaine Chai**

Associate Consultant,  
Department of  
Ophthalmology

Dr Chai graduated from the NUS, winning the Gold medal and Book Prize in Ophthalmology, and is one of the pioneering residents who completed her speciality training in NUH. Her special interest is in corneal and external diseases as well as cataract and refractive surgery, having contributed several book chapters in these fields. She is active in research, and has presented at several international conferences. Passionate in undergraduate education, she is also part of the Clinical Faculty Scheme of NUS.



**Dr Hazel Anne Lin**

Senior Resident,  
Department of  
Ophthalmology

Dr Lin graduated from NUS, having been on the Dean's list, and received the Margaret Lee Ming Yee Memorial Medal and Albert Lim Liat Juay Silver Medal. She started her ophthalmology residency in 2011, and obtained her Master of Medicine (Ophthalmology) in 2015, winning the Gold medal. In addition, she served as the Chief Resident of the department, and has been part of the Clinical Faculty Scheme in NUS. Dr Lin interests are in Neuro-ophthalmology and Cataracts.



## SPECIALIST IN FOCUS

## DR VICTOR KOH

Q1

**YOU HAVE KEEN INTERESTS IN THE INVENTION AND INNOVATION OF MEDICAL DEVICES IN THE FIELD OF OPHTHALMOLOGY. HOW DID THAT GET STARTED AND WHAT IS THE MOTIVATING FACTOR(S) FUELLING THESE PURSUITS?**

I believe that innovation is essential for improvement for the ophthalmologist because every micrometer, every degree, every mmHg counts towards better visual outcomes. The difference can be small but it goes a long way in preserving or even improving one's vision and quality of life. As a doctor, there are only a limited number of patients I can manage. However, with innovation and education, the patients who gain benefits are infinite. As a clinician, our understandings of the technology we use are only superficial, and frequently we accept the limitations too readily. As my mentor says: Yesterday we adapt to overcome the weakness of our tools, but today we have to innovate to let the instruments overcome our weakness. For this to happen, the clinician has to gain insights and in-depth understanding of the path that medical devices take before they become commercially available. It has been a humbling learning experience so far but I am fortunate to be mentored and supported in a nurturing environment at NUH. To overcome this challenge, I'm taking a part-time Masters

programme at NUS aimed at helping me to understand innovation and entrepreneurship better, so that I can fulfill my dream of turning ideas into devices which would make a difference to my patients' lives.

Q2

**COULD YOU SHARE WITH US ABOUT YOUR CURRENT PRACTICE AT NUH?**

I am currently an associate consultant at the Department of Ophthalmology, National University Hospital. My clinical interests are in glaucoma, cataracts, ocular trauma in the tertiary setting. I spend my time in the general clinics, glaucoma sub-specialty clinics and the operating room. I strongly believe that individualised eye care is the key for good visual outcomes and strive to provide patients with the latest and evidence-based treatment. With that in mind, my clinical commitment ties in nicely with my research interest, as I am also currently holding several competitive grants to study new and novel ways of detecting angle closure glaucoma and automated investigations. This combination will ensure that I am in tune with the latest diagnostics and therapeutics in tertiary eye care. My practice also incorporates ophthalmic education and I make it a point to teach medical students and residents during clinical sessions. The first thing I usually do is to build a good rapport with the

patients and this achieves two things – first, they have confidence in me and will more likely comply to their treatment regime. Second, they will trust me and are more willing to allow the medical students and residents to learn from them as I demonstrate the clinical signs.

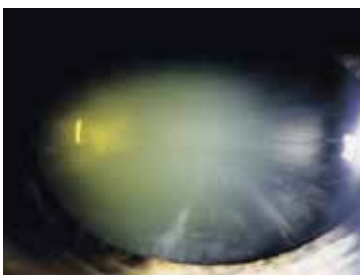

Image showing nuclear sclerosis cataract.

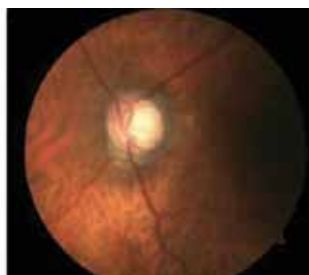
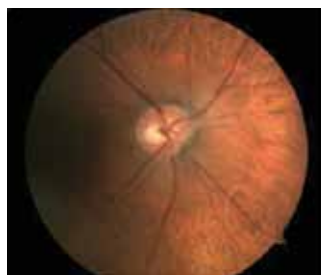
Image showing normal cup-disc ratio (left) and raised cup-disc ratio suggestive of glaucoma (right).



**Q3** **ARE EYE DISEASES SUCH AS GLAUCOMA AND CATARACTS BECOMING MORE COMMONPLACE IN SINGAPORE? HOW CAN GPs HELP TO FIGHT AGAINST SUCH DISEASES?**

Both glaucoma and cataracts share a common risk factor - old age. As the silver generation progress in Singapore, the incidence of both conditions also increase. According to World Health Organisation data, cataracts and glaucoma are the most common cause of visual impairment in the world. Although they are common, the prognosis and treatment are different. The common symptom for cataracts is painless, chronic blurring of vision for both eyes. The common risk factors include older age, ocular trauma and steroids use. Cataracts can be easily diagnosed by an ophthalmologist who will also rule out other pathology that blurs the vision. Modern cataract surgery is very effective and safe. Adjunctive techniques and wide range of intraocular lenses can also be implanted to suit the patient's visual needs including spectacle independence.

On the other hand, glaucoma tends to be asymptomatic until it has progressed to advanced stages with irreversible field loss. As such, screening for glaucoma is important and this includes checking the intraocular pressure (non contact methods are available), optic disc photographs (to detect raised cup-disc



ratio), strong family history of glaucoma and opportunistic eye screenings at the community level. In the primary care setting, a simple direct funduscopy can detect raised cup-disc ratio in the clinic. In Asia, angle closure glaucoma is particularly common and is at least three times more blinding than the open angle subtype. In acute angle closure resulting in a rapid rise in intraocular pressure, patients can present with acute frontal headache, nausea/vomiting, red eye and blurring of vision. The GPs need to have a high index of suspicion especially if the headache is not adequately controlled by first-line analgesia and patients presenting with repeat visits. In such situations, tonometry should be performed or the patient should be sent to the ophthalmologist with haste because early treatment is crucial for better long-term visual prognosis. The hallmark of glaucoma treatment is in the reduction of intraocular pressure. This can be achieved through eye drops, lasers, surgery or a combination of the above. Current management strategies are highly efficacious in preserving vision for glaucoma patients and recently there are many upcoming innovative treatment options. I understand that most of the ophthalmic equipment cannot be readily deployed at the GP setting due to various reasons which makes diagnosis of eye conditions challenging. This is also what fuels my research on medical devices with an aim to miniaturise and improve user friendliness for community



use. At the current moment, ideally, the GP should not hesitate and maintain a two-way communication channel with an ophthalmologist when in doubt. At NUH, we pride ourselves at supporting our primary healthcare colleagues readily and promptly so that patients can be triaged timely and accurately.

Q4

**YOU HAVE BEEN VOLUNTEERING AT COMMUNITY PROJECTS PROVIDING EYE SCREENINGS FOR LOCAL RESIDENTS, AND ALSO FOR OVERSEAS MISSION TRIPS. HOW HAVE THESE ACTIVITIES HELPED YOU IN YOUR PERSONAL AND PROFESSIONAL DEVELOPMENT?**

I believe in giving back because I have benefitted from the community. Along my training, I have learnt a lot from my patients and was given the privilege to treat them. Throughout the process, there were patients who I have successfully treated but the opposite is also true. Now that I am adequately trained, it is natural that the cycle is completed by using my skills to help as many patients as possible. Locally, I volunteered to organise and participate in eye screenings at various locations outside NUH and usually over the weekends. One of the major eye screenings is held in conjunction with Project Silvercare – a collaboration between St Luke's Hospital, NUH and Singapore Society of Ophthalmology. During these sessions, you can see how grateful the participants were and frequently, they belonged to the under-served

communities. It is humbling to see how people can cope independently even though they are visually impaired and staying alone without a caregiver. If the participants have any treatable eye diseases, we would then refer them to a tertiary eye centre with whatever assistance they require, such as financial support or transportation arrangement.

In Singapore, we are lucky to have world class eye care facilities but we are the anomaly in Asia. In many other less fortunate countries, accessibility to eye care is almost non-existent and people are blinded by cataracts which would be otherwise easily treated here. In a trip to Bangladesh in 2014, a team of four ophthalmologists from NUH, including myself, spent three days performing cataract surgeries in a make-shift operating theatre inside a classroom. We maximised our time by operating between 0800h and 2200h, and seeing the grateful faces of the villagers alone makes the effort worthwhile. We soon realised that many of these villagers spent many hours and even days to reach us so that they can have their surgeries! Although we have only operated on one eye each time, the almost-instant restoration of their vision meant that they can continue to work and provide for their family. We also visited Bangladesh Eye Hospital and gave talks on the latest management of diseases such as glaucoma and optic neuropathies. After every trip, I like to reflect on our situation and not take the current state in Singapore for granted. Personally, I look forward to the next trip already!

Q5

**WHAT BRINGS ON A SMILE TO YOUR FACE AFTER A LONG DAY**

Ultimately, after a long hard day at work, I will reflect on the good things that happened during my drive home – the smile on my patients' faces, the warm handshake of their family members, the resident whom I showed an interesting clinical sign, the high-risk surgery which went well and the joke which I shared with my colleague. However, nothing beats the hug from my wife and the kisses from my two boys when I reach home! Nothing.



**Dr Victor Koh**

Associate Consultant,  
Department of  
Ophthalmology

Dr Koh graduated from National University of Singapore in 2007 and passed his Ophthalmology Specialist Accreditation Examination in 2016. He has a keen interest in managing glaucoma, cataracts and ocular trauma. Dr Koh strongly believes that individualised eye care is the key for good visual outcomes, and strives to provide his patients with evidence-based treatment. He held several grants to develop novel devices/imaging tools to improve patient care, especially for glaucoma patients. He was awarded the NUS-NUH Young Educator Award 2014 and NUH Young Clinician Mentor Award 2015. He also served as Chief Resident from 2013 to 2014.

POST EVENT HIGHLIGHTS

# NUH EYE INTERNATIONAL CONFERENCE 3 – 6 NOVEMBER 2016

The NUH Eye International Congress 2016 was hosted by the NUH Ophthalmology Department in celebration of its 30th Anniversary. It was co-hosted by Asia-Pacific Ophthalmic Trauma Society (APOTS) which brings the combined meetings of XII International Society of Ocular Trauma and III APOTS. This meeting promised high quality and an enlightening adventure for ophthalmologists and trade partners alike. Emphasis was on new and emerging use of

information technology, the impact of health policy in the management of eye disease and visual loss. Multidisciplinary care of eye patients and rehabilitation of the visually handicapped have particular significance and were the main theme for this congress. We had a total of 678 participants representing up to 34 different countries. The preparation for this unique scientific meeting in Singapore was not easy and took more than one year of planning in advance. In this article, we bring you some of the highlights of the Congress.



## SCIENTIFIC CONTENT

For this unique meeting, each day was headlined by a morning forum which discussed broad perspectives within ophthalmology and how NUH has played a part in the evolution of ophthalmology in Singapore.

On 4 November 2016, we were honoured to welcome Dr Vivien Balakrishnan, Minister for Foreign Affairs, to speak on "Ophthalmology from a Global Perspective". The speaker is no stranger to us as he was a paediatric ophthalmologist by training and played a crucial role in starting the eye department in NUH. He revisited how public sector ophthalmology started as a nascent concept and eventually sculpted by the vision of the late Professor Arthur Lim, leading to the current world class facility in NUH. He emphasised on the importance of a holistic approach encompassing



evidence-based clinical service, comprehensive ophthalmic education and patient-centred research.

The forum was followed by the opening ceremony of the Congress which was graced by Dr Balakrishnan; Professor John Wong (NUHS Chief Executive), Associate

Professor Clement Tan (Head of Department); Associate Professor Paul Chew (Chairman of the Congress); Professor Clement Tham (Secretary-General of APAO).

The second day's topic was just as exciting and included an interesting list of speakers on "Innovation

in Ophthalmology". Professor Keith Barton spoke on the rapid influx and development of multiple innovative medical devices and implants, in particular on minimally invasive glaucoma surgery. Professor Paul Chew shared his own experience in developing the micropulse cyclotherapy







## TRAUMA PREMIER LEAGUE

The Trauma Premier League was a highlight of the ophthalmic trauma programme during the Congress. It comprised of a unique team-based video competition represented by two opposing teams, aptly named “Black Eyed Peas” (with reference to a 8-ball hyphema) and “Choroidal raptors” (a pun on choroidal ruptures)! The teams were led by Dr Michael Grant (Assistant Professor of Ophthalmology and Plastic Surgery at Wilmer Eye Institute, USA) and Dr Ferenc Kuhn (President of the International Society of Ocular Trauma). Each side featured challenging and complex videos on the management of ocular trauma in their practices. All the presenters were very sporting and wore their team t-shirts featuring mascots closely related to their team names. After a very enjoyable session with lively banter between the teams and judges, the crown was ultimately awarded to the team led by Dr Michael Grant, but not without much jesting!



device and the pathway towards commercialisation. We were also fortunate to have Professor Don Budenz (Chairman of Ophthalmology at the University of North Carolina, Chapel Hill, USA) to provide updates on sustained release IOP-lowering drugs for glaucoma patients. After listening from the clinicians’ perspective, the crowd also learned about the long and tenuous pathway towards commercialisation from an engineer and patent lawyer’s point of view.

Overall, the forum generated a great amount of interest amongst the budding medical innovators and we look forward to the upcoming APAO 2017 and



Ophthalmology Futures Meeting in 2017.

The third day’s forum is entitled “Future Retinal Technologies”. Professor Alan Bird, from Moorfield’s, spoke on future therapeutics in age-related macular degeneration, which includes stem cell therapy as an option in the near horizon. Dr Mandeep Singh, who did his PhD from Oxford on stem cells and is currently an Assistant Professor from John Hopkin’s, gave an overview of current techniques and advances in stem cell and gene therapy in ophthalmology. Lastly, Dr Boris Stanzel, who was trained in Germany, University of Bohn, presented his own work on RPE stem cell transplant in large animal models such as rabbits and non-human primates. Overall, the retina forum inspired the young ophthalmologists in our midst to pursue stem cell research as a career, as well as laid the foundation for future ophthalmology stem cell research in Singapore.



## ALUMNI ROUND TABLE

As a key tertiary eye centre in the region, we have been a training ground for overseas ophthalmologists pursuing higher learning in sub-specialty training for more than 20 years. Clinical and research fellows from all over the globe (with geographic distance stretching from our neighbouring ASEAN countries to Middle-east and Europe) had flown in to learn and call NUH their home. Up to date, NUH had trained more than 30 overseas ophthalmologists in sub-specialties such as glaucoma, oculoplastic, vitreo-retina, paediatric and refractive surgery, some of them even came twice to do different fellowships. During this light-hearted session, the alumni shared their past experiences during fellowship and their current work back in their own countries. In the presence of the senior faculty members, this session resembles more like a reunion!



# NUH OPHTHALMOLOGY 30<sup>TH</sup> ANNIVERSARY GALA DINNER


In celebration of the 30<sup>th</sup> Anniversary of the Department of Ophthalmology, NUH, a much anticipated gala dinner was held at the Grand Hyatt Hotel. We were honoured to receive guests from as many as 30 countries, esteemed

alumni, friends and colleagues from other institutions in Singapore. Everyone was treated to an evening of culinary delight, live musical performance and a customised sand-art show. This was the perfect opportunity to rekindle friendships and memories with everyone who was associated with the department at any one point throughout the 30 wonderful years. One of the highlights of the evening was a live performance by Professor Dan Milea and Professor Graham Holder who spent hours rehearsing their fantastic musical performance which was a delightful surprise for many of the guests.



## CHARITY ART AUCTION

The NUH Eye Charity Art Exhibition was organised for one purpose in mind – kindness. It is apt that we should celebrate the three decades of achievements by the Department of Ophthalmology by raising awareness to the visually impaired in Singapore. The exhibition also included an art auction to raise funds for the Guide Dogs Association of the Blind, and the Singapore Association of the Visually Handicapped. We were honoured to host Professor Vivian Balakrishnan, Minister for Foreign Affairs, for the opening ceremony. In total, we featured up to 67 art works by 37 artists and raised a total of SGD 23,000 with all the proceeds going to our beneficiaries.



## UPCOMING EVENTS

# DEVELOPMENTAL PAEDIATRICS UPDATES: MEDIA, SLEEP AND CHILDHOOD DEVELOPMENT

**NUHS TOWER BLOCK AUDITORIUM | 20 MAY 2017 | 2.00PM – 3.30PM**

Increasingly, our children face the issues of excessive media use and insufficient sleep. We aim to equip you with the knowledge and skills on media use and sleep practices in toddlers and young children. Through a case-based approach, we will cover two commonly encountered developmental problems, namely, global developmental delay and autism.





Media use has become ubiquitous in our society. From very young ages, children are increasingly exposed to all forms of media. Research has repeatedly showed that media exposure has powerful associations with impaired executive function, socialisation ability and sleep. Media use has also been associated with behavioural difficulties and obesity.

Our research on sleep behaviour in a sample of preschool children in 2012

showed that the duration of sleep in the Singapore preschool population sampled was significantly lower than recommended values than that of previously described populations. Parental perception of sleep adequacy also deviated from recommendations. Given the relationship between sleep duration and cognitive functioning, learning, attention and physical growth, identifying sleep issues should be a priority in the general practice setting.

Early intervention is the key to maximising the potential of young children with developmental delays and behavioural problems. Early identification and referral of these children are thus important in improving their outcomes. We hope to equip you with the skills to recognise these developmental problems in children as well as introduce some basic screening tools that you can use in your clinic.



TIME	TOPIC	SPEAKERS
2.00pm – 2.25pm	Screen and Media Use in Children	Dr Kalyani Vijaykumar Mulay Consultant 
2.25 pm – 2.50 pm	Addressing Sleep Issues in General Practice	Dr Jennifer Kiing Senior Consultant 
2.50pm – 3.10pm	Cases in Child Development – Global Developmental Delay	Dr Charmaine Teo Associate Consultant 
3.10pm – 3.30pm	Cases in Child Development – Autism Spectrum Disorder	Dr Serena Tung Consultant 

# GPLC

## NUH GP Liaison Centre

At the NUH, we recognise the pivotal role general practitioners (GPs) and family physicians play in providing and ensuring that the general public healthcare is of the highest quality and standard. As such, we believe that through closer partnerships, we can deliver more personalised, comprehensive, and efficient medical care for our mutual patients.

The GPLC aims to build rapport and facilitate collaboration among GPs, family physicians and our specialists. As a central coordinating point, we provide assistance in areas such as patient referrals, continuing medical education (CME) training, and general enquiries about our hospital's services. Through building these important platforms of shared care and communication, we hope that our patients will be the greatest beneficiaries.

**If we could be of any assistance to you, please feel free to contact our office from**

**Mon - Fri: 0900-1200hrs,  
1400-1800hrs**

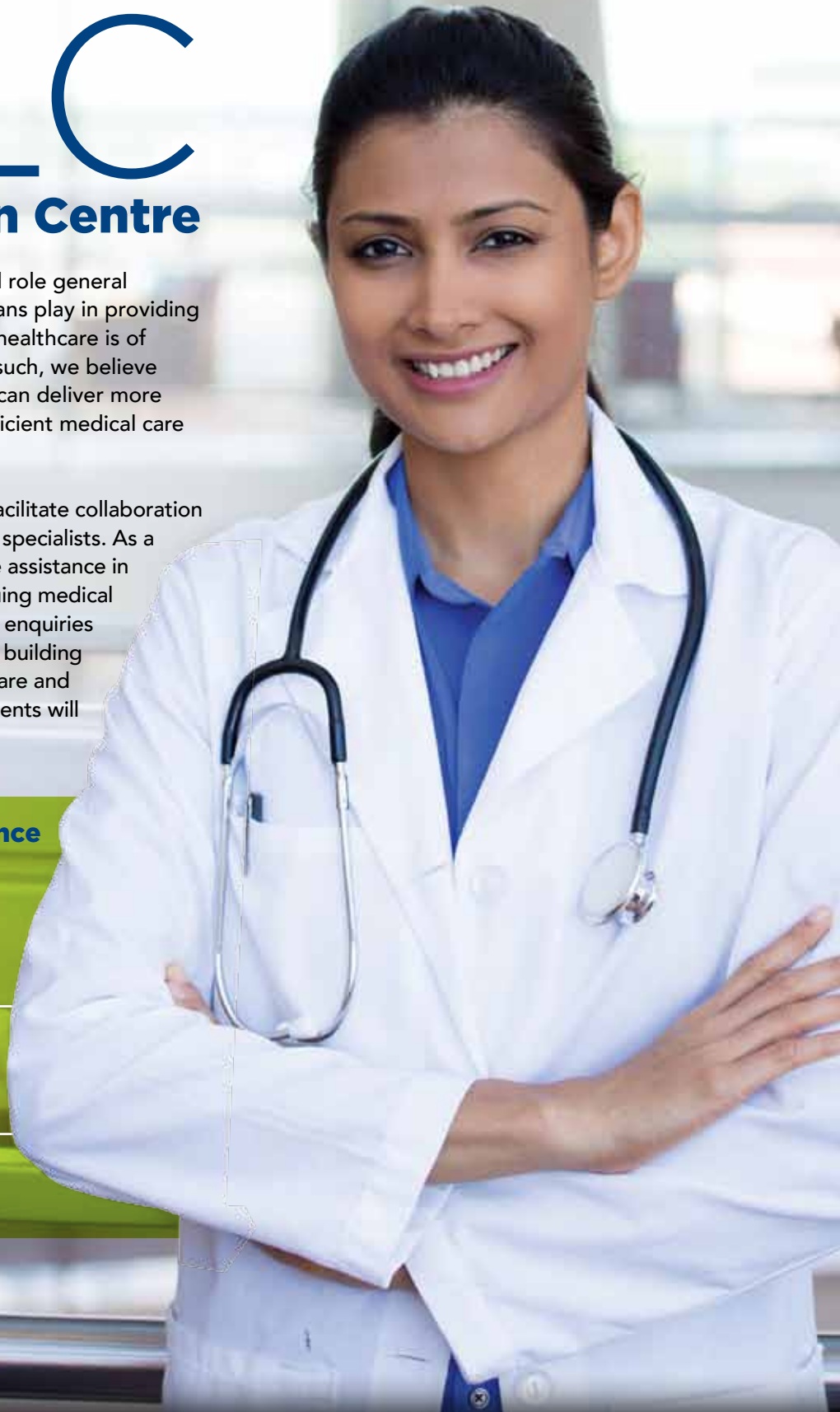
**GP Appointment Hotline**

**Tel: +65 6772 2000**

**Fax: +65 6777 8065**

**GP Liaison Centre**

**Tel: +65 6772 2535 / 5079**



## NUH CME EVENTS

At the NUH, we strive to advance health by integrating excellent clinical care, research and education. As part of our mission, we are committed to provide regular CME events for GPs and family physicians. These events aim to provide the latest and relevant clinical updates practical for your patient care.

Organised jointly by the GPLC and the various clinical departments within NUH, our specialists will present different topics in their own areas of specialties in these monthly symposiums.

For more information on our CME events, you can go to [www.nuhcme.com.sg](http://www.nuhcme.com.sg) or scan the following QR code.

