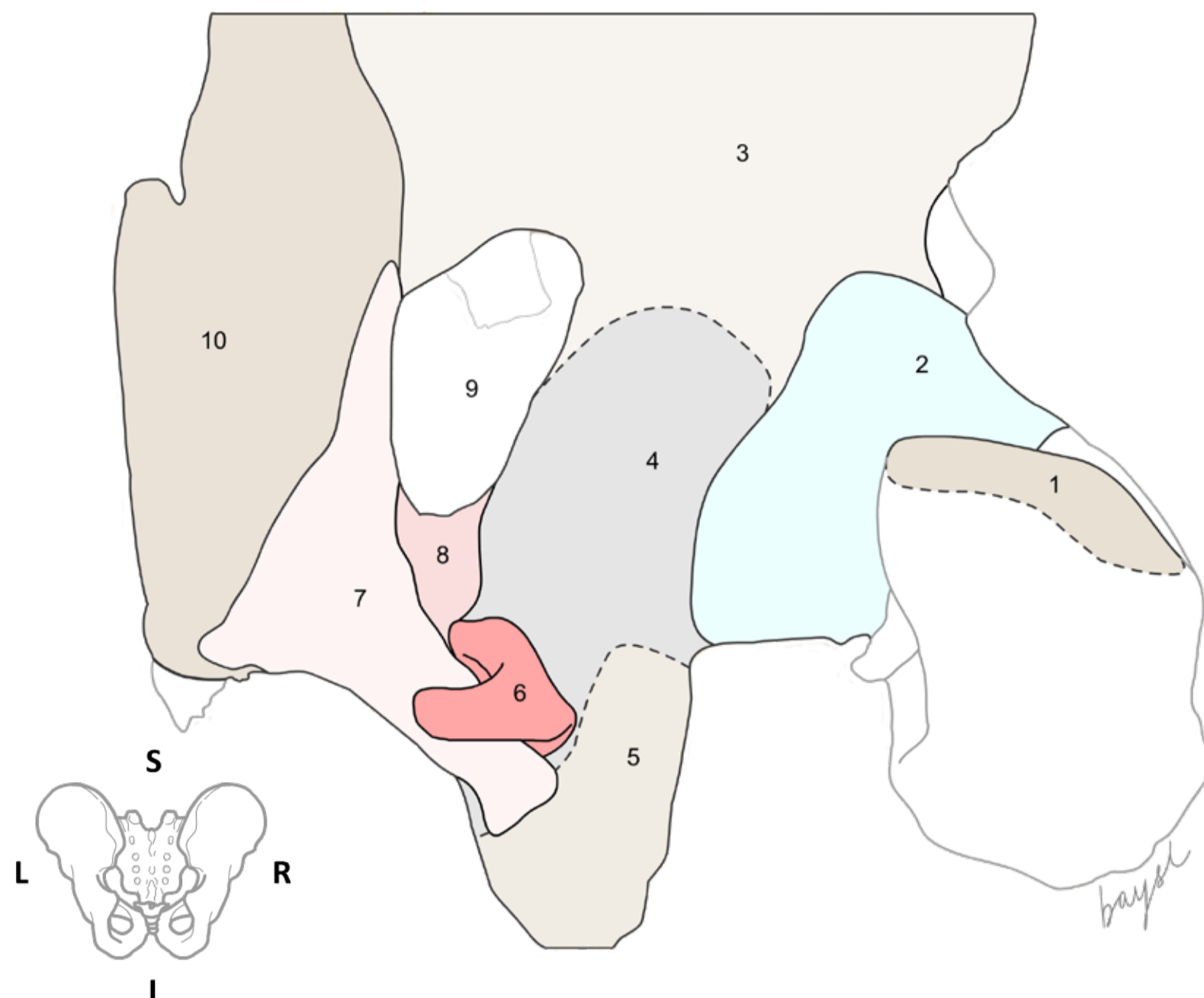


INNOMINATE BONE (HIP BONE)



Posterior view of the right hip bone, showing parts of the ischium and ilium; also showing the posterior aspect of the hip joint.

1. Greater trochanter
2. Capsule of hip joint
3. Ilium
4. Ischium
5. Ischial tuberosity
6. Obturator internus
7. Sacrotuberous ligament
8. Sacrospinous ligament
9. Greater sciatic foramen
10. Sacrum

The hip bone contributes to the formation of the following joints:

1. Hip joint (bilateral)
2. Sacroiliac joint (bilateral)
3. Pubic symphysis (mid-line)

The hip joint is a synovial 'ball and socket' joint. It is formed between the head of the femur and the acetabulum of hip bone. The joint cavity is enclosed by a fibrous capsule, which is attached to the margins of the acetabular labrum and the transverse ligament across the acetabular notch.

The sacrospinous ligament is a stabilizer of the sacroiliac joint; it connects the bony pelvis to the sacrum. The sacrospinous ligament is a triangular-shaped structure with its base attached to the sacrum (S2-S4) and coccyx, and its apex attached to the ischial spine. It forms the boundaries of the greater and lesser sciatic foramina which transmit nerves of the sacral nerve plexus that supplies the lower limb including the gluteal region, as well as the pelvis and perineum.

The sacrotuberous ligament helps to stabilize the sacroiliac joint and it connects the bony pelvis to the sacrum.

CLINICAL CONSIDERATIONS

Pudendal nerve entrapment between the sacrotuberous and sacrospinous ligament, or through its exit at the greater sciatic notch anterior to the sacrotuberous ligament, is one of the common causes of pudendal neurological manifestations that are more likely to cause sensory deficits.

Question(s)

- *What are the factors that contribute to the stability of the hip joint? List the major ligaments that are closely associated with the joint.*
- *What are the histological features of the capsule and ligaments associated with the hip joint? What is the innervation of the hip joint?*
- *What is the main function of the sacroiliac joint?*
- *Describe the origin, course and distribution of the pudendal nerve?*
- *What are the main features of the pubic symphysis?*